

# ANATOMIC EVALUATION OF SACROILIAC JOINT DIMENSIONS: AN IMAGING SERIES STUDY

Usman Latif MD, MBA<sup>1</sup>, Christopher Lam MD<sup>1</sup>, Sarah Keim Janssen PhD<sup>2</sup>, Nicholas Wharton MS<sup>3</sup>, Dawood Sayed MD<sup>1</sup>, Douglas Beall MD<sup>4</sup>, Timothy Deer MD<sup>5</sup>

## INTRODUCTION

Sacroiliac joint dysfunction is implicated in causing 15-30% of all non-radicular low back pain [1]. Several recent advances in interventional techniques have allowed for minimally invasive posterior fusion of the sacroiliac joint (SIJ). Traditional open and minimally invasive surgery involve a lateral fusion approach whereby an implant is placed from the lateral ilium into the sacrum and is associated with risks of vascular disruption of the superior gluteal artery and injury to the sacral nerves [2, 3]. The anatomic dimensions of the SIJ and the landmarks utilized for lateral implant placement, however, have not been formally studied. By understanding the statistical variations of the anatomy, it may be possible to decrease the incidence of neurovascular complications with lateral SIJ fusions. Here we present an imaging study of salient SIJ parameters to evaluate anatomic dimensions important for surgical planning.

## METHODS

Thirty-five subject Computed Tomography (CT) scans of the pelvis were obtained, evaluating 70 unique sacroiliac joints in total. With the level of measurement being defined as the midpoint of the level in the lateral view and the Sacral length defined as distance from the lateral aspect of the sacrum to the lateral aspect of the foramen, SIJ Gap defined as the distance between the medial aspect of the ilium and the lateral aspect of the sacrum, Iliac length defined as distance from lateral aspect of the ilium to the medial aspect, and SIJ length defined as the distance from the lateral aspect of the ilium to the lateral aspect of the foramen, measurements were taken for each joint. Descriptive statistics and 95% confidence intervals were calculated for each parameter.

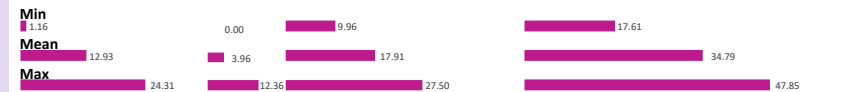
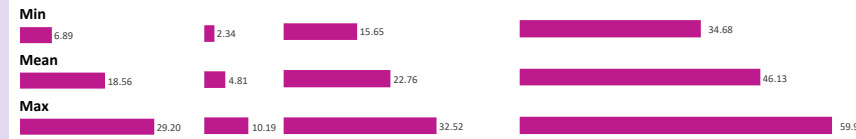

## RESULTS

Of the joints examined, the minimal sacral length, iliac length, SIJ gap, and total distance to lateral edge of S1 foramen were found to be 15.7, 6.9, 2.3 and 34.7 mm, while the maximal lengths were 32.5, 29.2, 10.2, and 59.9 mm, respectively (Table 1). For the S2 level, the minimal sacral length, iliac length, SIJ gap, and total distance to lateral edge of S2 foramen were found to be 10.0, 1.2, 0.00, and 17.6 mm, while the maximal lengths were 27.5, 24.3, 12.4, and 47.9 mm, respectively.

## PRIOR LITERATURE

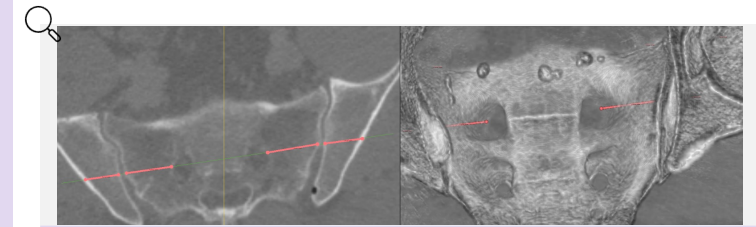
The anatomy of the sacrum is highly variable between males and females in terms of size, shape, and contour. The SIJ is formed by the S1 and S2 sacral segments with variable inclusion of S3 between the sexes [4]. Studies have shown that measurements from the lateral sacral mass (LSM) (par lateralis) to the anterior S1 foramina average 29 mm, and 22.8 mm to the anterior S2 foramina. The mean width posteriorly of the LSM to the posterior foramina was 24.3 mm at S1 and 18.6 mm at S2 [5].

Sacroiliac foramen encroachment is unlikely with a lateral fusion if the implant is less than 34.7 mm in length at the S1 level and 17.6 mm in length at the S2 level

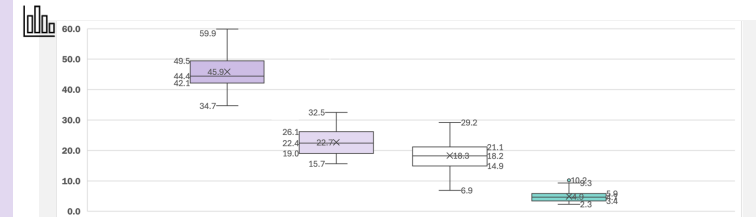


70 SI Joints	Sacral Length				Iliac Length				SI Joint Gap			
	Mean	Min	Max	95% CI	Mean	Min	Max	95% CI	Mean	Min	Max	95% CI
1st Foramen	22.76	15.65	32.52	14.6-30.9	18.56	6.89	29.20	9.5-27.6	4.81	2.34	10.19	1.6-8.0
2nd Foramen	17.91	9.96	27.50	10.6-25.2	12.93	1.16	24.31	3.8-22.1	3.96	0.00	12.36	0.2-7.7

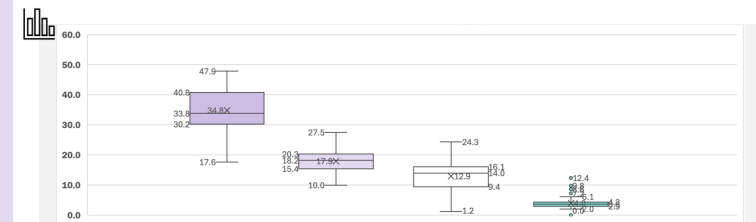
Total SI Joint	Total Distance to Lateral Edge of Foramen			
	Mean	Min	Max	95% CI
1st Foramen	46.13	34.68	59.92	34.7-57.6
2nd Foramen	34.79	17.61	47.85	21.4-48.2



Lateral measurement at level matching the most lateral aspect of the sacral foramen



Box and whisker plots for total length, sacral length, iliac length, and SIJ gap at the 1<sup>st</sup> foramen



Box and whisker plots for total length, sacral length, iliac length, and SIJ gap at the 2<sup>nd</sup> foramen

## CONCLUSION

Our results within are the first to delineate the statistical variations of the SIJ for the purpose of refining the lateral SI joint fusion technique. This study of 70 SI joints revealed that the minimum distance to the lateral edge of the foramen was 34.7 mm (S1 level) and 17.6 mm (S2 level). These findings may help improve the safety and efficiency of lateral SIJ implant placement.

### Affiliations

- The University of Kansas Health System, Department of Anesthesiology, Kansas City, KS 66160, USA
- The University of Kansas Health System, Department of Surgery, Kansas City, KS 66160, USA
- LightSource Research, Houston, TX 77002, USA
- Comprehensive Specialty Care, Edmond, OK 73034, USA
- The Spine and Nerve Centers of the Virginias, Charlottesville, WV 25301, USA

### References

- Cohen, S.P., Y. Chen, and N.J. Newfield. Sacroiliac joint pain: a comprehensive review of epidemiology, diagnosis and treatment. *Spinal Res Neurother*. 2021; 13(1): p 96-116.
- Lee, D.W., D.G. Patterson, and D. Sayed. Review of Current Evidence for Minimally Invasive Posterior Sacroiliac Joint Fusion. *Global Spine J*. 2019; 29(14): p 2453-2463.
- Shimizu, T., et al. The Safety Profile of Percutaneous Minimally Invasive Sacroiliac Joint Fusion. *Global Spine J*. 2019; 29(14): p 2464-2473.
- Vierming, A. Schumke MD, Masi AT, Carrizo JE, Danneels L, Willard FN. The sacroiliac joint: an overview of its anatomy, function and potential clinical implications. *J Anat*. 2012 Dec;221(6):637-67.
- Esenkaya I, Akucuk MA, Kavakli A, Bulut HF. Lateral sakral kilitlerin morfolojik ve radyolojik degerlendirilmesi [Radiologic and morphologic evaluation of the lateral sacral mass]. *Acta Orthop Traumatol Turc*. 2005;37(4):330-9

### Acknowledgements

Special thanks to Spinal Simplicity and LightSource Research for their support of this research.

### Corresponding Author

Usman Latif, MD, MBA  
Associate Professor  
The University of Kansas Health System  
✉ dlatif@gmail.com